

Dear Friends

Greetings from warm, sunny Tenwek Hospital!

I want to give you an encouraging update on a young patient we have been taking care of for six months. Bernard, a 25-year-old young man, was admitted to Tenwek Hospital on July 3rd 2008. He was working with a group of men in a wheat field during the wheat harvest when, unfortunately, he fell off from the top of a combine harvester. If you have seen a combine harvester, you will know that his fall from the roof was quite a height! He landed on the harvesting apparatus and then bounced down to the ground, after which the wheel of the harvester rolled over his abdomen and pelvis. As you might imagine, he suffered tremendous injuries: his pelvis was crushed badly, and he had multiple internal abdominal injuries. In addition, due to the extreme force administered to his body, he suffered esophageal perforation. This is an unusual injury that can occur when there is a large amount of force applied to the chest. After dealing with his abdominal injuries, we eventually had to open his chest, and it was only then that I realized the extent of his injuries. I discovered an extremely large tear in his esophagus. Unfortunately, he had eaten a meal recently and there was excessive contamination of food material inside his chest. This, combined with the length of time it took to get Bernard from the accident scene to the hospital, made it impossible to repair that injury at that time. Instead, I elected to remove the majority of his esophagus with the plan to repair it at a later date. This necessitated bringing the first part of his esophagus out the side of his neck, much like a colostomy is used for colon surgery. This means that all food, all saliva, anything that goes in his mouth, comes out the side of his neck into a colostomy bag. He was then fed completely by a tube placed in his stomach. After considerable thought and evaluation of his severe pelvic injury, we elected to place him in a very unusual type of traction to attempt to bring back together his very badly displaced pelvic fracture, which extended into the hip joint. He was therefore confined to bed with traction pins applied to his femur and pelvis for twelve weeks. During that time, Bernard was fed purely through a tube in his stomach. As you might expect, it took him quite a bit of time to heal. He lost a significant amount of weight and eventually dropped to about 85 pounds. As you can imagine, he was very anxious to have his esophagus repaired so that he could once again take food by mouth. However, we told him that would be very unwise given the extent of his injuries and malnourished state. I told him that I would not consider operating on him until he had gained at least back to 50 kg, or approximately 110pounds.

We find it very difficult to maintain effective tube feedings at home; we therefore elected to keep him in the hospital until he had gained that weight back. By mid-December, Bernard had eventually gained back weight up to 52 kgs and he was walking very well out of traction. The holiday season is a busy time to try to schedule such large operations as Bernard would need, but I knew he was anxious to have his esophagus reconstructed so that he could eat food by Christmas. So on December 16th, I took him back to the operating room and began the long operation to reconstruct his esophagus using his stomach. After the tremendous injuries he had suffered, we could not use the normal path that the esophagus usually sits in, and had to choose a new path which brought his esophagus to the front of his chest in front of his heart instead of being in the back of his chest. This then allowed the stomach to be brought up into his neck where it could be re-attached to his esophagus.

He continued to be fed by tubes for a week and on December 23rd; he took his first drink in over six months. By December 24th, he had his first coca cola that he had enjoyed since July, and on Christmas day he took his first meal of solid food. As you might imagine, Bernard was overjoyed to be eating once again!

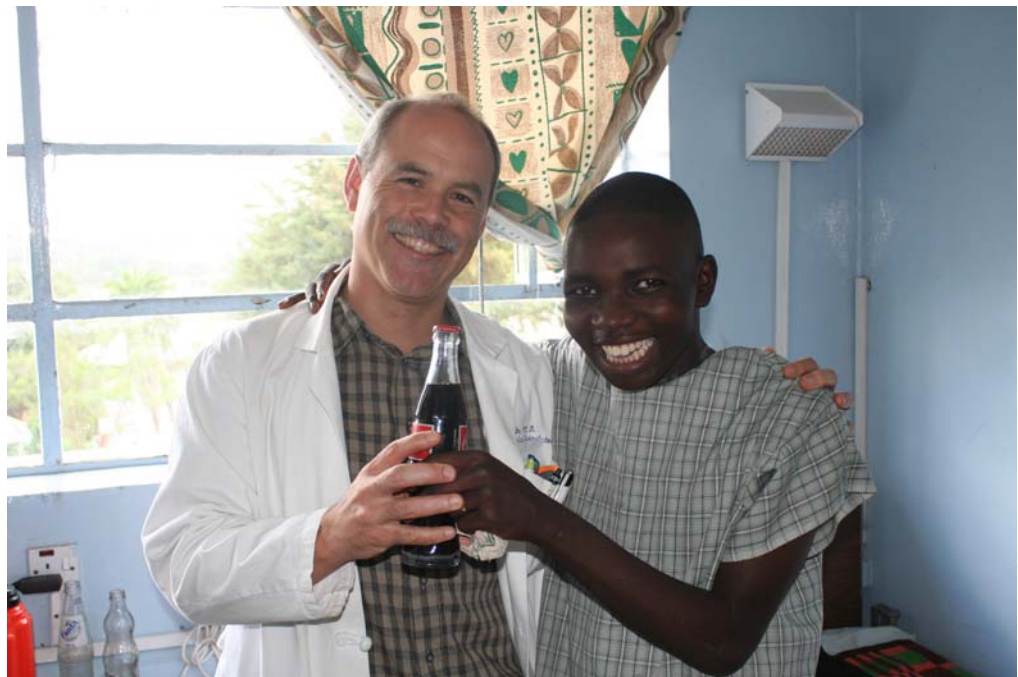
Bernard is a young Christian who gave his life to Jesus only several months before coming to Tenwek Hospital. During the six months he was at Tenwek, he had extensive time to read his Bible and be discipled by our chaplaincy staff. His family said that no one in his home area continued to believe he was alive given the long time he was away. He was discharged home in time to be there for the New Year. His village was thrilled and amazed to see him healthy again. We are planning a crusade to be held in his home village to share with the entire village the news that not only can Jesus heal the body, but He can also heal the soul.

Please join us in thanking God for the tremendous recovery of Bernard and pray that God will use his experience to bring many to saving knowledge of Jesus Christ.

It continues to be my privilege to work at Tenwek Hospital helping people like Bernard. I want to thank so many of you who uphold me and my family in your prayers and with your financial support allowing us to be here to do the work which God has called us to at Tenwek Hospital.

In His service

Russ White
Tenwek Hospital



Bernard drinks his first coke on Christmas day after six months with nothing to eat or drink!

Contact us:

email: russ.white@wgm.org

For support:

World Gospel Mission
P.O. Box 948
Marion, IN 46952

On the field:

Tenwek Hospital
Box 39
Bomet 20400 KENYA

Tenwek Hospital * We Treat, Jesus Heals